



**THE INTERNATIONAL MOUNTAINEERING AND CLIMBING FEDERATION**  
**UNION INTERNATIONALE DES ASSOCIATIONS D'ALPINISME**

Office: Monbijoustrasse 61 • Postfach  
CH-3000 Berne 23 • SWITZERLAND  
Tel.: +41 (0)31 3701828 • Fax: +41 (0)31 3701838  
e-mail: office@uiaa.ch

---

# **OFFICIAL STANDARDS OF THE UIAA MEDICAL COMMISSION**

## **VOL: 20**

### **Eye Problems on Expeditions**

Intended for Doctors, Interested Non-medical Persons  
and Trekking or Expedition Operators

**D.S. Morris, S. Mella, D. Depla**

**2010**

## **1. Introduction**

Visual loss in the wilderness setting is potentially fatal. Firstly it may be a warning sign of a serious systemic problem and secondly the patient may lose their functional independence and ability to respond to objective danger.

The issues discussed in this paper fall broadly into two categories, those that are unique to the high altitude setting and those that could happen anywhere but require treatment to protect vision when standard ophthalmological care is unavailable. The aims are to provide practical knowledge on how to manage simple eye problems and also how to recognise the warning signs when evacuation may be required.

In keeping with all wilderness medicine, preparation and prevention are essential to avoid eye problems in the mountains. This paper is intended for physicians, interested non-medical people and expedition operators as a practical guide to the treatment and prevention of eye problems on expeditions.

## **2.0 Expedition preparation**

### **2.1 Pre-expedition medical assessment**

The expedition doctor should be aware of any pre-existing ocular conditions or medical problems which may have ocular complications. With this in mind, the questions below should be built into the pre-expedition medical assessment:

1. Do you wear contact lenses?
  - If yes what type are they? (eg hard/soft, monthlies/dailies)
2. Have you ever been treated by a doctor for an eye problem?
3. Have you ever had laser eye surgery or any other eye operation on your eyes?
  - If yes what type and when?
4. Does anyone in your family suffer from glaucoma or any eye disease?
5. Are you diabetic?

### **2.2 Pre-existing ocular conditions**

The only ocular condition which excludes ascent to high altitude or even air travel is the immediate post-operative period following the use of intraocular gas in retinal surgery as this can expand and potentially cause a central retinal artery occlusion (Polk et al). For more chronic eye diseases other precautions may need to be taken and regular medication should not be forgotten in the expedition environment.

#### **2.2.1 Monocular vision**

People with useful vision in only one eye should take extra care to protect their eyes from both the sun and objective dangers such as sand, ice and rock. It is therefore advisable to have specially designed polycarbonate safety glasses for any activities where flying debris could enter the eye.

### **2.2.2 Refractive errors**

Refractive error can be corrected by spectacles, contact lenses, surgery or even a pinhole in a piece of cardboard. As a general rule, the best way to prevent problems is to use the same method of correction as you would at home and not try to suddenly change, for example, from spectacles to full time contact lens wear on an expedition. If you wear spectacles take a spare pair and get your prescription built into a pair of sunglasses or glacier goggles. Contact lenses and refractive surgery are discussed in further detail below (see section 6.0 and 7.0).

### **2.2.3 Cataract surgery**

There are no special precautions required for people who have an intraocular lens following cataract surgery or clear lens extraction who want to ascend to high altitude. Although no formal studies have been performed to confirm this statement, there is plenty of anecdotal evidence from mountaineers, aviators and even astronauts!

### **2.2.4 Glaucoma**

People on drops to reduce their intraocular pressure (IOP) should continue them as normal. There is a theoretical risk of hypoxic damage to the optic nerve head at high altitude exacerbating their glaucoma so they should consult their ophthalmologist before ascent. The use of acetazolamide could be considered for its combined effect on acute mountain sickness (AMS) and its ability to decrease IOP. Exercise itself will also help to decrease IOP.

### **2.2.5 Diabetes**

There is no evidence that high altitude causes or exacerbates diabetic retinopathy (Leal et al). Diabetic people also do not appear to be at any greater risk of high altitude retinopathy. However diabetics should maintain strict glycaemic control and acclimatise sensibly to avoid systemic or ocular consequences. It would also be sensible to have a full eye examination approx. 6 months before going on any expedition so that if any treatment is required there would be time for the course of treatment to be completed.

### **2.2.6 Retinal surgery**

As mentioned above, if a person has recently had retinal surgery with intra-ocular gas they should not go into any environment where atmospheric pressure is changed: this includes air travel and high altitude. There is some evidence that retinal detachment may be induced at high altitude (Morris et al 2007) in susceptible individuals but once a detachment has been repaired successfully, there should be no risk at altitude.

## **3. Snow blindness**

Snow blindness is caused by unprotected exposure of the cornea and conjunctiva to ultraviolet (UV) light, specifically UV-B. Snow blindness is therefore sunburn of the eye and can be extremely painful. Like sunburn, there is a delay between UV exposure and the onset of symptoms so by the time that the patient realises that they

have snow blindness, the damage has already been done. **Note:** Lay persons should be advised to remember the symptoms of snow blindness may develop even at night in the tent or hut when there was a high exposure earlier in the day.

Snow blindness is more common at high altitude because the air is thinner so more UV light penetrates the atmosphere. On ascent, UV exposure increases by 4% for every 300 metre climb. In addition, snow reflects 80% of UV light greatly increasing the chances of snow blindness (WHO). So it can take just a few minutes of unprotected exposure to cause debilitating snow blindness on a glacier at altitude.

Snow blindness is characterised by red, painful, gritty eyes with photophobia (aversion to light): many patients find it impossible to keep their eyes open. The conjunctiva will be red where it has been exposed to light and the cornea will show punctate staining with fluorescein drops. Treatment includes local cooling (e.g. with cool, damp compresses), antibiotic ointment (Oc. Chloramphenicol tds), cycloplegic drops to relieve the pain of ciliary spasm (G. Cyclopentolate tds), rest and light avoidance. Recovery is usually within 24 hours but beware of secondary infection as snow blindness renders the eye vulnerable. Note: Avoid local anaesthetic eyedrops as these slow corneal re-epithelisation and so prevent healing and increase risk of infection. Such drops should be used to allow examination and confirm no other causative pathology and to allow emergency evacuation from a perilous position if necessary. A greasy eye dressing with double padding can aid comfort for the first night and nonsteroidal anti-inflammatory drugs make good oral analgesics to treat ocular pain. If the eyes are left unpadded but numbed from the examination make sure the patient doesn't sit unblinking as this will exacerbate the condition,

Avoidance of snow blindness is simply with sunglasses blocking all UV transmission, preferably of good quality (CE/EN protection class 3 or 4 and 100% UV protection) with protective sidepieces, or with goggles. These should be worn at all times in snow, especially at high altitude. In emergency, sunglasses can be made from a piece of bark or cardboard with small slits in it tied around the head. Porters are just as vulnerable to snow blindness, so don't forget to give them sunglasses too! The authors applaud initiatives by porter welfare organisations who are encouraging expedition leaders to provide their porters with eye protection.

#### **4. High altitude retinopathy**

High altitude retinopathy (HAR) is a pathological response by the retina to the hypoxia of altitude and it was first described in 1969 (Singh et al). Flame shaped haemorrhages are most commonly seen but optic disc swelling, cotton wool spots, dot and blot, pre-retinal and vitreous haemorrhages have also been reported.

Although HAR is usually asymptomatic, when a haemorrhage occurs over the macula, vision can be affected. Previous studies have shown an incidence of HAR from 3.8% to 90.5% with an equal preponderance in males and females (Clarke and Duff, Wiedman and Tabin). However it appears that about one quarter of people ascending to moderate altitude in the Himalayas are affected by asymptomatic HAR. The pathophysiology of HAR is unknown but highest altitude attained, rate of ascent and exertion appear to be risk factors (Morris et al).

There is only anecdotal evidence to suggest a relationship between HAR, acute mountain sickness (AMS), high altitude cerebral oedema (HACE) and high altitude

pulmonary oedema (HAPE). However retinal vascular dysregulation could herald similar problems in other organs and should not be taken lightly. Optic disc swelling may indicate early HACE so should also be monitored as suggested below.

#### **4.1 High altitude retinopathy grading system**

The authors suggest the following VHD grading system for HAR which can be applied by any physician with an ophthalmoscope: Three aspects of HAR should be examined in each eye individually, vision (V), haemorrhages (H) and optic disc swelling (D) in order to guide management.

##### **4.1.1 Vision**

- V0- vision is unaffected
- V1- vision is decreased (in any respect: acuity, contrast sensitivity or colour vision)
- V2- vision is lost completely.

##### **4.1.2 Haemorrhages**

- H0- No haemorrhages but engorged and tortuous retinal vessels.
- H1- one to three retinal haemorrhages less than 2 disc diameters in total area.
- H2- Four or more retinal haemorrhages or more than 2 disc diameter in total area. Any evidence of cotton wool spots or vitreous haemorrhage.

##### **4.1.3 Optic Disc**

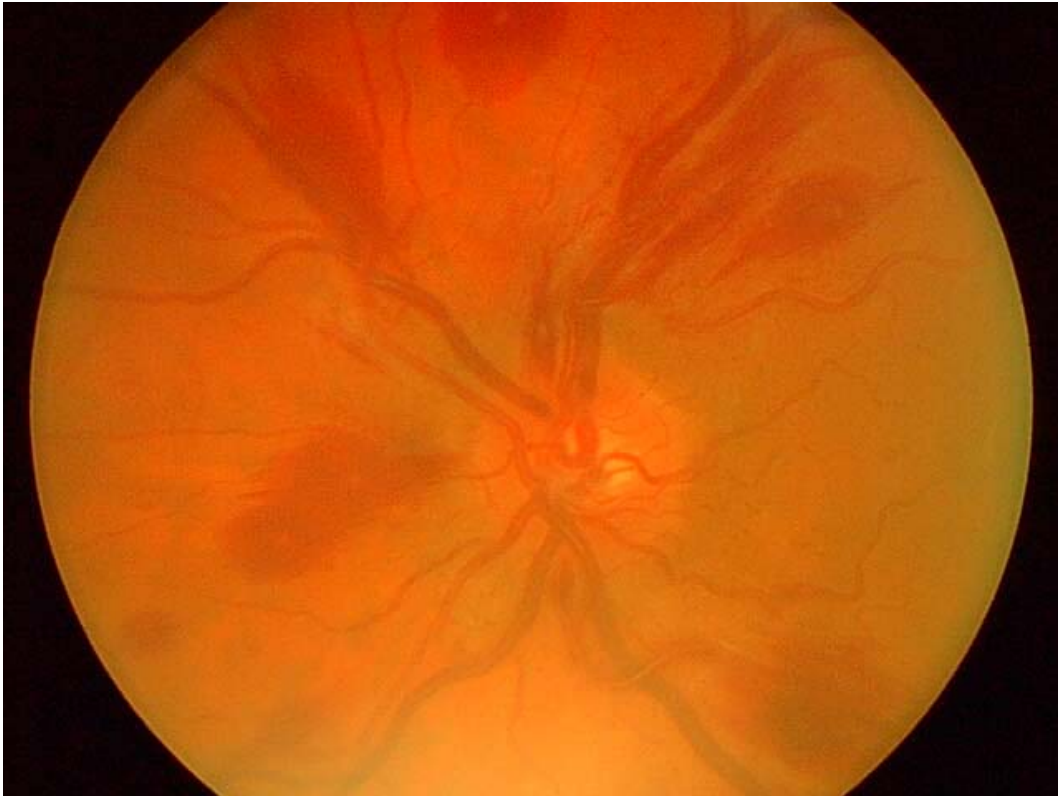
- D0- Normal optic disc
- D1- Mild disc swelling
- D2- Frank papilloedema.

#### **4.2 High altitude retinopathy management**

Patients with either V1, H2 or D1 should not ascend any further and should be closely observed for signs of visual loss, AMS, HACE or HAPE.

Patients with either V2, or D2 should descend at least 300m with oxygen until the condition resolves and should be closely monitored. Any concurrent AMS, HACE or HAPE should be treated aggressively to prevent potentially fatal sequelae.

As with any altitude illness, each case should be managed individually in the context of any systemic signs and the ease of evacuation should it be required.



**Figure 1:** High altitude retinopathy at 5400m.

There was no change in vision but widespread haemorrhages and mild optic disc swelling. It was therefore graded V0-H2-D1 using the scheme described above. The patient also had severe AMS and descended 500m for 3 days before making an uneventful ascent to 7400m.

## **5. Loss of vision**

### **5.1 Painful loss of vision**

Painful loss of vision should be of great concern to the expedition doctor. A full examination should be performed and it is important to confirm if the patient has had any previous eye problems. If a cause can be found it should be treated but there should be a low threshold for evacuation and specialist ophthalmological intervention. Possible causes include acute angle closure glaucoma, uveitis, optic neuritis, orbital cellulitis, bacterial keratitis and snow blindness.

### **5.2 Painless loss of vision**

Loss of vision in one or both eyes, even transiently, should be taken very seriously. A full history should be taken before checking the pupil reactions and if possible dilating the pupils with tropicamide 1% for examination with an ophthalmoscope. If no cause is found the patient should be evacuated for specialist assessment. The differential diagnosis includes retinal detachment, retinal artery or vein occlusion, cerebral ischaemia, HACE, HAR, ischaemic optic neuropathy, vitreous haemorrhage and malignant hypertension.

## 6. Contact lenses

Contact lens users are vulnerable to dry eyes and serious corneal infection in the expedition setting so they should be advised on sensible contact lens use (no more than 8 hours a day), strict hygiene when handling lenses and to take plenty of spare lenses as well as spectacles to wear when they are not using their contact lenses.

Any potential infection, even what appears to be a simple conjunctivitis, should be taken very seriously. Contact lens wear should be stopped and intensive broad spectrum antibiotic drops should be started (eg ofloxacin hourly). If there is no improvement within 5 days the patient should be evacuated.

There is no evidence to suggest that contact lenses should not be worn at high altitude (Flynn et al) but remember that they reduce oxygen delivery to the cornea which can lead to corneal oedema and so blurred vision even at sea level and at altitude there will be less available oxygen. Of preference the authors would recommend the use of daily disposable soft contact lenses over other types as they have a high water content, allow a high transmission of oxygen to the cornea and require less handling with no cleaning, making infection less likely.

## 7. Refractive surgery and altitude

Refractive surgery is popular with active people who enjoy sports and outdoor recreation so that they can avoid the use of spectacles and contact lenses. However altitude can transiently affect the visual outcome which could be life-threatening. This was famously demonstrated by Dr Beck Weathers attempting to climb Mount Everest in 1996 after he had radial keratotomy (Krakauer).

A general trend towards long-sightedness has been found in subjects at altitude who have had RK (where deep radial cuts are made in the cornea) (Mader and White). This appears to be related to swelling of the corneal stromal fibres on either side of the keratotomy incisions as a result of the low atmospheric oxygen, causing the weakened cornea to expand circumferentially, making the eye longsighted. Hypoxia reduces accommodation by an effect on the parasympathetic nervous system. Most subjects who have had this sort of treatment are of an age where accommodation is already reduced (onset of presbyopia) and the hypoxia induced hypermetropia outstrips the available accommodation making the subject longsighted and unable to focus clearly, especially for near tasks. One possible answer would be to take spare "reading glasses" of +1.00, +2.00 or +3.00 to use as distance glasses under glacier goggles when necessary.

Radial keratotomy has now been superseded by excimer laser keratectomy where a laser is used to shave off part of the cornea to alter the refractive power. This can be done either after removing the corneal epithelium (PRK), making a flap out of the corneal epithelium which is then replaced (LASEK) or creating a flap which include corneal epithelium and anterior stroma (LASIK). These newer techniques cause less change at high altitude but can still cause a shift towards short-sightedness, first reported in 2000 when a climber who had received LASIK experienced blurred vision at 19,500 feet which cleared on descent (White and Mader).

There is also an element of individual susceptibility as many people who have had refractive surgery experience no problems whatsoever at altitude. However patients should be advised not to have refractive surgery within 3 months of an expedition as

refraction can be unstable and the eye is at risk of infection. Any infection or decreased vision in a patient who has had refractive surgery should be taken seriously and descent should be considered.

## **8. Dry eyes**

Dry eyes are more common in the dry, windy, bright conditions found at high altitude or in polar regions (Gupta et al). Although often just a nuisance, severely dry eyes are very painful, can significantly blur vision and leave the eyes vulnerable to infection.

The main symptoms of dry eyes are red, painful, gritty eyes and any ocular lubricants can be used as treatment. Bear in mind that the more viscous ointments provide a longer period of relief but blur vision even further. Contact lens wear should be minimised in patients with symptomatic dry eyes and remember that goggles or wrap-around sunglasses can decrease evaporation of tears from the eyes and therefore decrease symptoms.

## **9. Trauma**

### **9.1 Corneal abrasion**

A corneal abrasion is a tear in the corneal epithelium usually through mild trauma, such as removing a contact lens or perhaps even whilst asleep. It is exquisitely painful and topical anaesthetic will provide immediate relief, but should not be used as a treatment. Fluorescein will confirm the diagnosis and treatment is with antibiotic ointment (e.g. Chloramphenicol tds). An eye pad is not usually necessary and can encourage infection.

### **9.2 Corneal foreign body**

Occasionally the protective blink reflex fails and allows a foreign body to embed itself into the cornea. This can be metallic or organic and a metallic foreign body will often leave a rust ring. The mechanism of injury should be ascertained as a high velocity foreign body is more likely to penetrate the globe (such as a shard of metal from an ice-axe.)

A corneal foreign body will cause a red, painful gritty eye and the sensation that something is in the eye. The foreign body is usually very small but fluorescein and a magnifying loupe can assist identification and removal, either with a cotton bud or a 25G needle. Patients should then be given antibiotic ointment (eg Chloramphenicol ointment tds). Eversion of the upper eyelid should be performed to exclude a sub-tarsal foreign body.

### **9.3 Chemical injury**

A chemical splash can be sight-threatening so immediately irrigate profusely, preferably with sterile normal saline. Check the pH with litmus paper if available (see appendix 1) and continue irrigation until pH is 7. It is important to identify the chemical as alkali penetrates the ocular tissues much faster than acid and therefore has a

worse prognosis. Treatment should include antibiotic ointment (e.g. chloramphenicol tds), lubrication (e.g. artificial tears hourly) and cycloplegic drops (e.g. cyclopentolate tds) for pain relief. Note that a white eye in the acute phase could indicate severe ischaemia and evacuation for specialist treatment is indicated if there is any concern.

#### **9.4 Eyelid laceration**

The eyelids play an important role in protecting the eye and preventing corneal desiccation. If they are damaged, the eye can be rendered vulnerable. The underlying eye should always be checked for a penetrating injury to the globe, especially if the mechanism of injury was high velocity. The wound should be examined carefully and cleaned if necessary. If the lid margin is interrupted and the ends are not opposed, primary repair under local anaesthesia should be considered. This is especially important with the upper lid to prevent corneal exposure. If repair is not possible, apply plenty of antibiotic ointment (e.g. chloramphenicol tds) and patch the eye if you are concerned about exposure.

#### **9.5 Penetrating eye injury**

A penetrating eye injury involves disruption of the globe integrity and is a serious, sight-threatening problem. The mechanism of injury is important in determining whether there could be an intraocular foreign body or a perforating injury (entry and exit). A high suspicion of penetrating injury should be maintained in any high velocity high injury, such as those involving firearms or hammering. Signs to be looking for include decreased vision, a soft watery eye, a peaked pupil (not round) and expulsion of ocular contents.

Any suspected penetrating eye injury should be immediately evacuated for specialist treatment. Broad-spectrum systemic antibiotics should be started and any expelled ocular contents should not be touched; antibiotic ointment and a pad should be applied to the eye.

#### **9.6 Blow-out fracture and blunt trauma**

Blunt trauma to the globe (for example from a fall or a punch) can cause the bony orbital floor to fracture tethering the inferior rectus muscle and limiting upgaze. This causes double vision, a sunken eye and pain on eye movement. The double vision may be intolerable in which case the damaged eye should be patched.

Remember that blunt trauma can cause many other problems within the eye, such as hyphema, subluxed lens, vitreous haemorrhage, retinal detachment and globe rupture. If visual acuity is decreased, consider evacuation for specialist evaluation.

#### **10.0 Conclusion**

Ophthalmology is viewed by the general physician with anything from mild boredom to abject fear. Unfortunately these fears may have to be faced in the expedition setting and this paper is designed to equip people with the tools required to assess and treat an eye problem in the wilderness setting

Visual acuity is the single most important sign when examining the eye and a chart is not necessarily required. Simply ask the patient if their vision has changed, compare the two eyes by covering one then the other or use an old magazine. Acute eye problems are often very painful, so it is important to remember the role of systemic analgesia in treatment.

Preparation is vital to prevent eye problems on expeditions, especially ensuring that everyone including porters have adequate eye protection. In the event of a visual problem, it is always better to be cautious and evacuate a patient rather than a risk a sight-threatening or even life-threatening complication.

## References

1. Clarke C, and Duff J. Mountain sickness, retinal haemorrhages and acclimatisation on Mount Everest in 1975. *Br Med J*.ii: 495-497, 1976.
2. Flynn WJ, Miller RE 2nd, Tredici TJ, Block MG. Soft contact lens wear at altitude: effects of hypoxia. *Aviat Space Environ Med*. 1988 Jan;59(1):44-8.
3. Gupta N, Prasad I, Himashree G, D'Souza P. Prevalence of dry eye at high altitude: a case controlled comparative study. *High Alt Med Biol*. 2008 Winter;9(4):327-34.
4. Krakauer J. *Into Thin Air: A Personal Account of the Mount Everest Disaster*. London: Random House; 1998.
5. Leal C, Admetlla J, Viscor G, Ricart A. Diabetic retinopathy at high altitude. *High Alt Med Biol*. 2008 Spring;9(1):24-7.
6. Mader TH and White LJ. Refractive changes at extreme altitude after RK. *Am J Ophthalmol* 1995;119:733-737.
7. Morris DS, Severn PS, Smith J, Somner JEA, Stannard KP, Cottrell DG. High altitude and retinal detachment. *High Alt Med Biol*. 2007, 8(4): 337-339.
8. Polk JD, Rugaber C, Kohn G, Arenstein R, Fallon WF Jr. Central retinal artery occlusion by proxy: a cause for sudden blindness in an airline passenger. *Aviat Space Environ Med*. 2002 Apr;73(4):385-7.
9. Singh I, Khanna PK, Srivastava MC, Lal M, Roy SB, Subramanyam CS. Acute mountain sickness. *N Engl J Med* 1969;280(4):175-84.
10. White LJ and Mader TH. Refractive changes at high altitude after LASIK. *Ophthalmol* 2000;107(12):2118.
11. Wiedman M and Tabin GC. High Altitude Retinopathy and Altitude Illness. *Ophthalmol* 106: 1924-1927, 1999.
12. World Health Organisation. Ultraviolet radiation and the INTERSUN programme. World Meteorological Organization. 1992 [accessed 16 May 2010]. Available from: [http://www.who.int/uv/uv\\_and\\_health/en/](http://www.who.int/uv/uv_and_health/en/).

## Further reading

1. Morris DS, Somner J, Donald MJ, McCormick IJ, Bourne RR, Huang SS, Aspinall P, Dhillon B. The eye at altitude. *Adv Exp Med Biol*. 2006;588:249-70.
2. Mader TH, Tabin G. Going to high altitude with preexisting ocular conditions. *High Alt Med Biol*. 2003 Winter;4(4):419-30.

3. Ellerton JA, Zuljan I, Agazzi G, Boyd JJ. Eye problems in mountain and remote areas: prevention and onsite treatment--official recommendations of the International Commission for Mountain Emergency Medicine ICAR MEDCOM. *Wilderness Environ Med.* 2009 Summer;20(2):169-75.
4. Johnson C, Anderson SR, Dallimore J, Winser S, Warrell DA. *Oxford Handbook of Expedition and Wilderness Medicine.* Oxford: Oxford University Press; 2008.

**Members of UIAA MedCom (in alphabetical order)**

C. Angelini (Italy), B. Basnyat (Nepal), J. Bogg (Sweden), A.R. Chiocconi (Argentina), N. Dikic (Serbia), W. Domej (Austria), P. Dobbelaar (Netherlands), E. Donegani (Italy), S. Ferrandis (Spain), U. Gieseler (Germany), U. Hefti (Switzerland), D. Hillebrandt (U.K.), J. Holmgren (Sweden), M. Horii (Japan), D. Jean (France), A. Koukoutsis (Greece), A. Kokrin (Russia), J. Kubalova (Czech Republic), T. Kuepper (Germany), J. McCall (Canada), H. Meijer (Netherlands), J. Milledge (U.K.), A. Morrison (U.K.), H. Mosaedian (Iran), R. Naeije (Belgium), M. Nakashima (Japan), S. Omori (Japan), P. Peters (Luxembourg), I. Rotman (Czech Republic), V. Schoeffl (Germany), J. Shahbazi (Iran), J.C. Skaiaa (Norway), J. Venables (New Zealand), J. Windsor (U.K.)

**Guest Authors of UIAA MedCom (in alphabetical order)**

D. Depla (Ophthalmology Department, Cumberland Infirmary, Carlisle, UK)  
S. Mella (University of Cardiff Medical School, Cardiff, UK)  
D. Morris (Cardiff Eye Unit, University Hospital of Wales, Cardiff, UK)

**History of this recommendation paper**

This paper was approved by written consent in lieu of a meeting at Nov.30<sup>th</sup>. 2010

## Appendix 1

### Ocular First Aid Kit

The first aid kit listed below is lightweight and should fit into a small pouch. However as an expedition doctor you should have some experience of using a loupe and ophthalmoscope as well as administering eye drops and applying a double eye pad.

#### *Equipment*

- Pentorch +/- blue filter
- Pocket ophthalmoscope
- Magnifying loupe
- Eye pads (4)
- Eye shield
- Surgical tape
- pH paper
- Minor operation kit

#### *Drops*

- Minims:
  - Amethocaine/Benoxinate (topical anaesthetic)
  - Fluorescein 1% (use only after topical anaesthetic) Why only after topical anaesthetic?
  - Cyclopentolate 1% (pupil dilation and pain relief)
  - Artificial tears (dry eyes and snow blindness)
  - Tropicamide 1% (for pupil dilation)
  - Pilocarpine 2% (for reversal of pupil dilation by tropicamide) Use in this way risks precipitating angle closure glaucoma so I would not recommend it in the older age groups.
- Others:
  - Chloramphenicol ointment (4 tubes) (any minor infection or snow blindness)
  - Ofloxacin (more serious infection and all contact lens-related infection)
  - Sodium cromoglycate (allergic conjunctivitis)
  - FML (mild steroid, use cautiously) **Note:** Do not apply any steroid drug locally in case of snow blindness or any corneal damage! I wouldn't use steroid in the presence of a dendritiform epithelial lesion but some people feel that a little topical steroid can reduce inflammation and so make the eye more comfortable, esp. in snowblindness.

These 4 drops given four times daily except ofloxacin which can be given hourly for serious infection. *Remember oral analgesia such as a nonsteroidal anti-inflammatory if not contra-indicated, as required, for a painful eye.*